

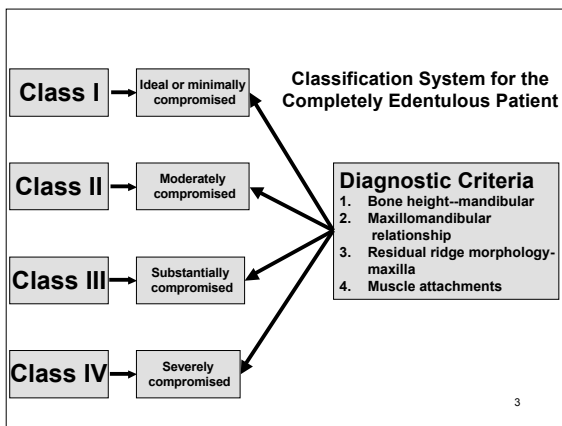
Monday, April 23, 2007

1

American College of Prosthodontics

Classification of the Completely Edentulous Patient

2



3

Diagnostic Criteria

1. Bone height--mandibular
2. Maxillomandibular relationship
3. Residual ridge morphology-maxilla
4. Muscle attachments

4

Bone Height Mandibular

①

5

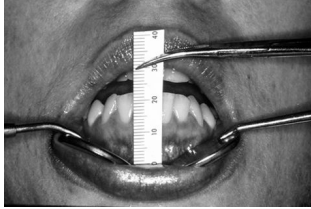© Bone Height - Mandibular

Quantity of the Underlying Bony Foundation

- Denture foundation area
- Tissues remaining for reconstruction
- Loss of facial muscle support/attachment
- Decrease in total facial height
- Residual ridge morphology

6

Classification of Alveolar Atrophy



John H. Kent, D.D.S.
LSU Medical Center,
New Orleans

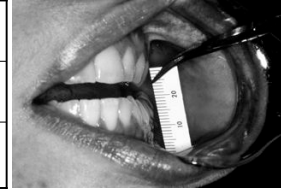Alveolar measurements

Incisal edge to vestibule	19mm
Alveolar crest to vestibule	10mm

7

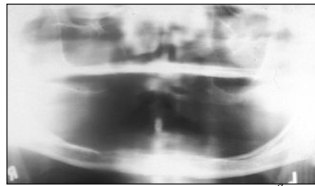
Alveolar Measurements

Occlusal plane to inferior border	40mm
Mental nerve to inferior border	15mm
Alveolar crest to inferior border	32mm



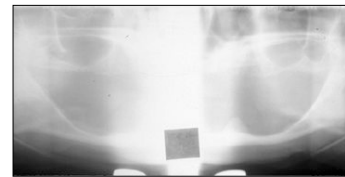
8

The objectivity of residual bone height measurement is affected by the magnification and variance of radiographic procedures and equipment of different manufacturers.

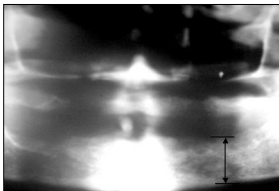


However, this diagnostic measurement reveals the most information of all the criteria.

In order to minimize variance in techniques, the measurement should be made at that portion of the mandible of the least vertical height.



Type I



Residual bone height of 21mm or greater measured at the least vertical height of the mandible.

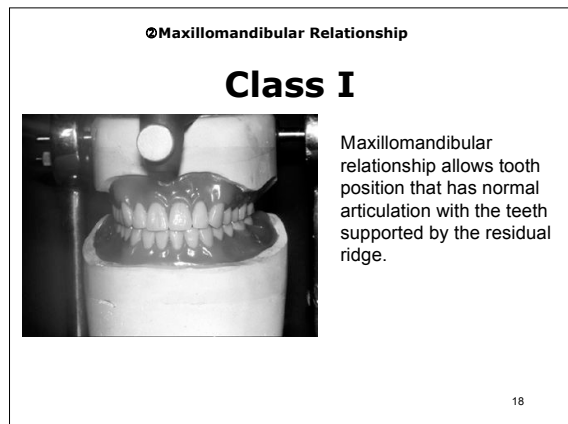
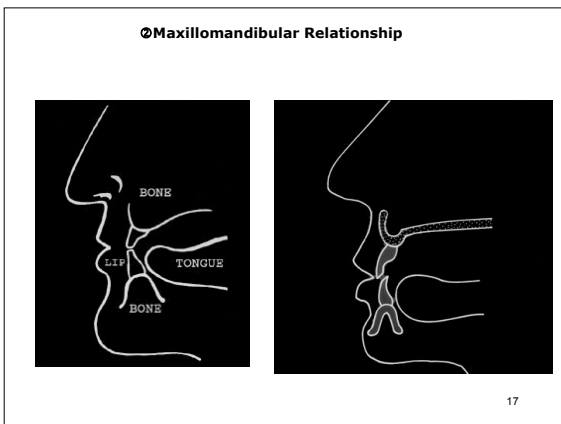
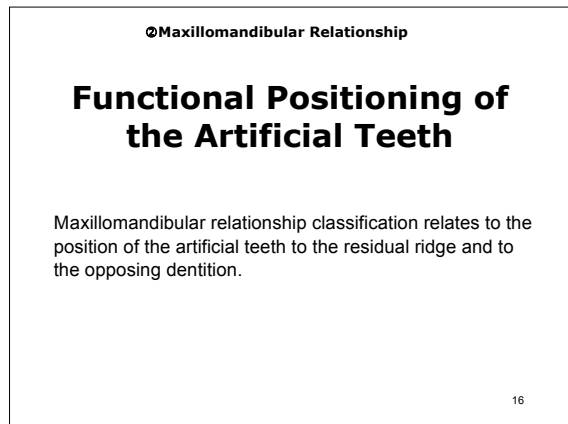
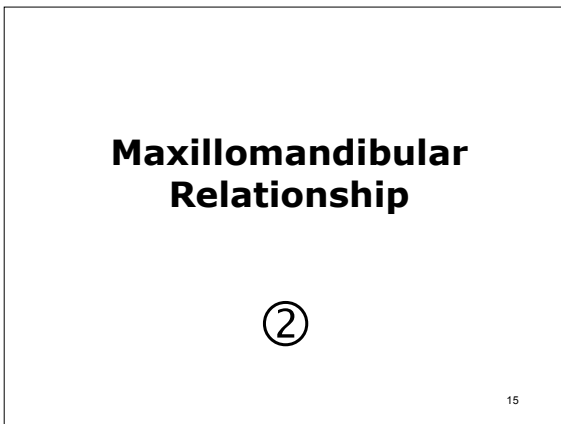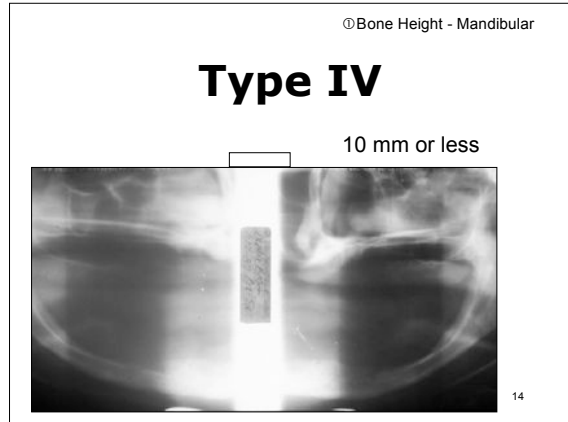
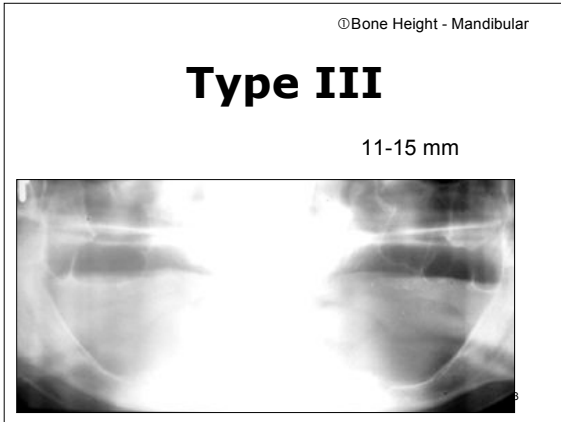
11

Type II

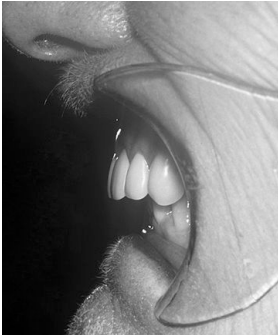16-20 mm measured at the least vertical height of the mandible.



12



©Maxillomandibular Relationship



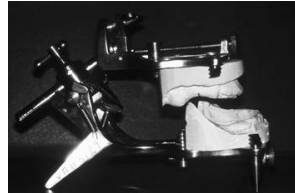
Class II

Maxillomandibular relationship requires tooth position outside the normal ridge relation in order to attain phonetics and articulation; i.e., anterior or posterior tooth position not supported by the residual ridge/anterior vertical overlap that exceeds the principles of articulation.

19

©Maxillomandibular Relationship

Class III

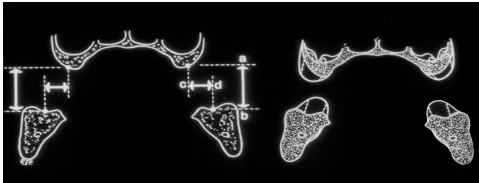


Maxillomandibular relationship requires tooth position outside the normal ridge relation in order to attain phonetics and articulation; i.e., crossbite— anterior or posterior, tooth position not supported by the residual ridge.

20

©Maxillomandibular Relationship

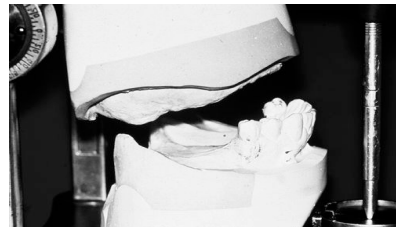
Complete Edentulism



21

©Maxillomandibular Relationship

Position and Angulation of the Occlusal Plane



22

Residual Ridge Morphology: Maxilla

③

23

③ Residual Ridge Morphology: Maxilla

Residual ridge morphology is the most objective criteria for the maxilla since measurement of the residual bone height by radiography is not reliable.

24

Type A

Maxilla

- Hard Palate form
- Anterior Maxilla
- Maxillary Tuberosities

25

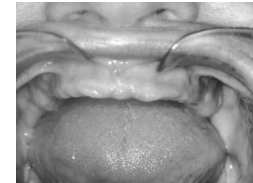Anterior labial and posterior buccal vestibular depth that resists vertical and horizontal movement of the denture base

Palatal morphology that resists vertical and horizontal movement of the denture base

Sufficient tuberosity definition that resists vertical and horizontal movement of the denture base

Hamular notch is well defined to establish the posterior extension of the denture base

Absence of tori/exostoses



26

Type B

Maxilla

- Hard Palate form
- Residual Alveolar Ridge
 - Anterior
 - Posterior
- Maxillary Tuberosities

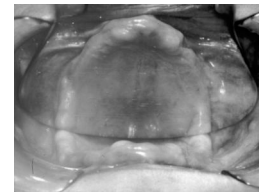
27

Loss of posterior buccal vestibule

Tuberosity and hamular notch are poorly defined compromising delineation of the posterior extension of the denture base

Maxillary palatal and/or lateral tori are rounded and do not affect the posterior extension of the denture base

Palatal vault morphology that resists vertical and horizontal movement of the denture base



28

Type C

Maxilla

- Hard Palate form
- Anterior Maxilla
- Maxillary Tuberosities

29

Loss of anterior labial vestibule

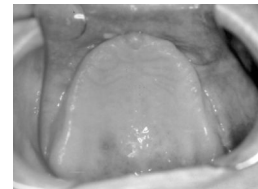
Prominent midline suture

Maxillary palatal and/or lateral tori with bony undercuts that do not affect the posterior extension of the denture base

Hyperplastic, mobile anterior ridge that offers minimum support and stability of the denture base

Palatal vault morphology that offers minimal resistance to vertical and horizontal movement of the denture base

Reduction of the post malar space by the coronoid process during mandibular opening and/or excursive movements



30

Type D

Maxilla

- Hard Palate form
- Residual alveolar ridge
 - Anterior
 - Posterior
- Maxillary Tuberosities

31

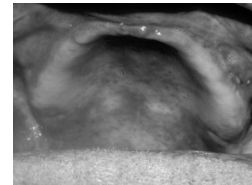
Loss of anterior labial and posterior buccal vestibules

Maxillary palatal and/or lateral tori-rounded or undercut- that interferes with the posterior border of the denture

Hyperplastic, redundant anterior ridge

Palatal vault morphology that does not resist vertical or horizontal movement of the denture base

Prominent anterior nasal spine



32

Muscle Attachments

④

33

④ Muscle Attachments

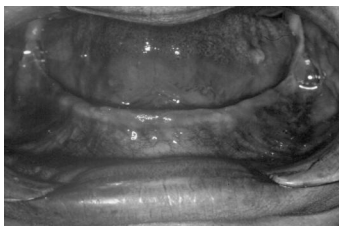The location and influence of the muscle attachments affecting a complete denture are most commonly associated with the mandibular denture

Describes the effects of muscular influence on the mandibular denture

34

Type A

Adequate attached mucosal base without undue muscular impingement during normal function in all regions.

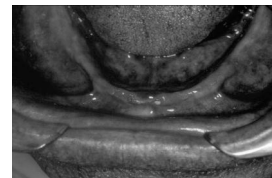

35

Type B

Adequate attached mucosal base in all regions except anterior buccal vestibule—cuspid to cuspid

High mentalis muscle attachment



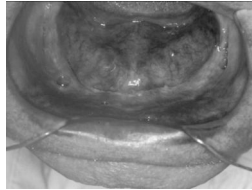
36

Type C

④ Muscle Attachments

Adequate attached mucosal base in all regions except anterior buccal and lingual vestibules—cuspid to cuspid

High genioglossus and mentalis muscle attachments



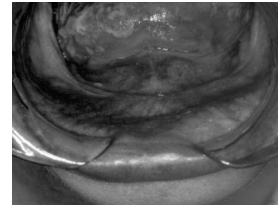
37

Type D

④ Muscle Attachments

Adequate attached mucosal base only in the posterior lingual region

All other regions are detached



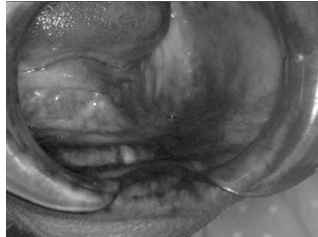
38

Type E

④ Muscle Attachments

No attached mucosa in any region

Cheek and lip movement = tongue movement



39

Diagnostic Classification of Complete Edentulism

40

Class I

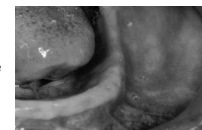
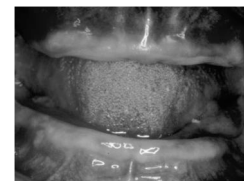Most apt to be successfully treated by conventional prosthodontic techniques with complete denture prosthesis.

All four of the diagnostic criteria are favorable.

41

Class I

- Residual bone height of 21 mm or greater measured at the least vertical height of the mandible
- Class I maxillomandibular relationship
- Residual ridge morphology that resists horizontal and vertical movement of the denture base—Type A—Maxilla
- Location of muscle attachments that are conducive to denture base stability and retention—Type A, B—Mandible



42

Class II

Continuation of the **physical degradation** of the denture supporting structures,

Characterized with the **early onset of systemic disease** interactions,

Localized **soft tissue** factors, and

Patient **management/lifestyle** considerations

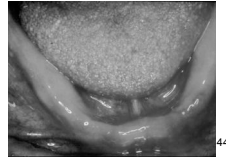
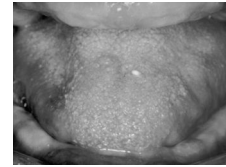43

Class II

•Residual bone height of 16-20 mm measured at the least vertical height of the mandible

•Class I maxillomandibular relationship

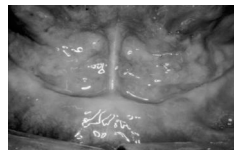
•Residual ridge morphology that resists horizontal and vertical movement of the denture base—Type A, B—Maxilla



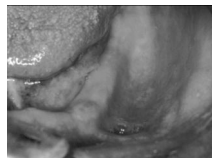
44

Class II

Location of muscle attachments with limited influence on denture base stability and retention
Type A,B—Mandible



Minor modifiers, psychosocial considerations, mild systemic disease with oral manifestations and localized soft tissue conditions



45

Class III

Need for surgical revision of denture supporting structures to allow for adequate prosthodontic function.

Additional factors now play a significant role in treatment outcomes.

46

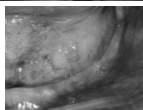
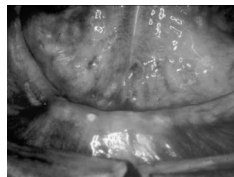
Class III

Residual bone height of 11-15 mm measured at the least vertical height of the mandible

Class I, II and III maxillomandibular relationship

Residual ridge morphology has minimum influence to resist horizontal or vertical movement of the denture base—Type C—Maxilla

Location of muscle attachments with moderate influence on denture base stability and retention—Type C—Mandible



47

Class IV

Most debilitated edentulous condition.

Surgical reconstruction is almost always indicated but can not always be accomplished due to the patient's health, desires, past dental history and financial considerations.

When surgical revision is not selected, prosthodontic techniques of a specialized nature must be used in order to achieve an adequate treatment outcome.

48

Minor conditions requiring preprosthetic surgery:

- Minor soft tissue procedures
- Minor hard tissue procedures
- Implant placement (simple)--no augmentation required
- Multiple extractions leading to complete edentulism for immediate denture placement
- Limited interarch space—18-20 mm

49

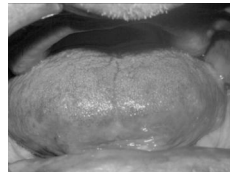
Other minor conditions :

- Moderate psychosocial considerations and/or moderate oral manifestations of systemic diseases or localized soft tissue conditions
- TMD symptoms present
- Large tongue with or without hyperactivity
- Hyperactive gag reflex

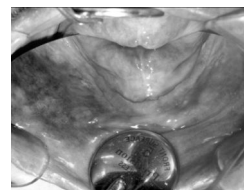
50

- Residual bone height of least vertical height of the mandible
- Class I, II and III maxillomandibular relationship
- Residual ridge offers no resistance to horizontal or vertical movement – Type D—Maxilla
- Location of muscle attachments with significant influence on denture base stability and retention— Type D and E--Mandible

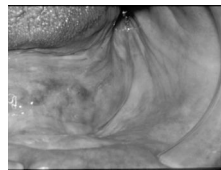
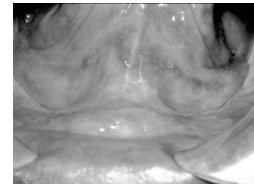
Class IV



51



Class IV



52

Major conditions which require preprosthetic surgery

- Implant placement (complex)—augmentation required
- Surgical correction of dentofacial deformities
- Hard tissue augmentation
- Major soft tissue revision, i.e., vestibular extensions with or without soft tissue grafting
- History of paresthesia or dysesthesia
- Insufficient interarch space with surgical correction required
- Acquired or congenital maxillofacial defects

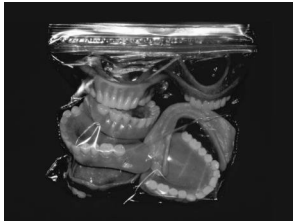53

Other major conditions :

- Severe oral manifestation of systemic disease or conditions including sequelae from oncologic treatment
- Maxillomandibular ataxia (incoordination)
- Hyperactivity of tongue that can be associated with a retracted tongue position and/or its associated morphology
- Hyperactive gag reflex managed with medication
- Psychosocial conditions warranting professional intervention

54

- **Refractory patient** (a patient who has chronic complaints following appropriate therapy). These patients continue to have difficulty in achieving their treatment expectations despite the thoroughness or frequency of the treatment provided.



55

Guidelines for use of the Complete Edentulism Classification System

- In those instances when a patient's diagnostic criteria are mixed between two classes, any single criteria of a more complex class will move the patient into that respective class.
- Utilization of this system is indicated for pre-treatment evaluation and classification of patients. Retrospective analysis on a post-treatment basis may alter a patient's final classification

56